

By Laura M Periman, MD and Leslie E. O'Dell, OD

# Beauty doesn't have to hurt

We take a look at exacerbators of Ocular Surface Disease in cosmetics cabinets.



**Laura M. Periman, MD,** is a cornea and refractive surgery trained ophthalmologist in Redmond, Wash. Her interests in immunopathophysiology started as a research and development associate at Immunex Corp. in the 1990s. She can be reached at lauramperimanmd@gmail.com.

**Leslie E. O'Dell, OD** bio.....

About the Authors

Prescription medications that we recommend for our dry eye disease (DED) patients have been proven safe and efficacious through rigorous clinical trial studies. But the products and cosmetics that our patients use in and around their eyes — which have the potential to exacerbate or contribute to the disease<sup>1</sup> are not required to meet that standard. The assumption is that cosmetics do not have a toxic local or systemic effect. Do we know if this is true?

The Federal Food, Drug, and Cosmetic Act of 1938 was enacted after 100 people died because diethylene glycol (related to anti-freeze) was used to solubilize a sulfanilamide.<sup>2</sup> Since then, attempts to update the law have failed.

The FDA defines cosmetics by their intended use, as “articles intended to be rubbed, poured, sprinkled, or sprayed on, introduced into, or otherwise applied to the human body...for cleansing, beautifying, promoting attractiveness, or altering the appearance”.<sup>3</sup> The cosmetics labeling laws on the FDA web site note that “ingredients *must* be declared in descending order of predominance” and “Ingredients present at a concentration not exceeding 1% *may be listed* in any order after the listing of the ingredients present at more than 1% in descending order of predominance.”<sup>3</sup> This is problematic for allergy patients and dermatitis patients.

Also, when you read cosmetics ingredients lists carefully, you’ll see that several potentially damaging ingredients and preservatives to the ocular surface are listed without percentages. Given the 1% labeling laws, it is possible that the potentially tear-film-disrupting and epithelial toxic ingredients and preservatives are not

only present but are quite possibly at levels much higher than you would find in a prescription eyedrop. In the case of eye makeup removers, the alcohol and BAK load may have daily access to the delicate eyelid margins and conjunctiva and thereby contribute to that patient’s OSD. Additionally, no specific cosmetics safety tests are required and companies are not required to share their safety data with the FDA.<sup>4</sup>

## A little test:

Consider the ingredient list of this top-selling department store make-up remover. Can you identify the seven ingredients most likely to be hard on the tear film and goblet cells?

*Aqua, water, eau, cyclopentasiloxane, isohexadecane, sodium chloride, poloxamer 184, hexylene glycol, dipotassium phosphate, benzyl alcohol, potassium phosphate, quaternium-15, benzalkonium chloride, parfum, fragrance, citronellol, geraniol.*

There is more to makeup than adorning the eye. We will explore ingredients in everyday products and their impact on the ocular surface.

## EVERYDAY CHEMICALS

### Sodium laureth sulfates

A top selling, dermatologist-recommended facial wash may be ideal for use around the face, but may overstrip the delicate oils/meibum found in the eyelid’s skin and meibomian glands. This action, in turn, may contribute to the evaporative load of OSD patients. Facial washes/cleaners often contain sodium laureth sulfates that dissolve the natural oils of the face and eyelids.

*Cosmetics continued on page 32*

**Cosmetics** continued from page 27

Mouse models of desiccating stress reveal that the pro-tein:lipid ratio of mature meibum suffers under the increased demands of desiccating stress in a controlled adverse environment (CAE).<sup>5</sup> The surfactants impart the feeling of

However, you won't see 'formaldehyde' written on any cosmetic ingredients list. *Formaldehyde-donating preservatives in cosmetics* are hidden under the unpronounce-able: DMDM-hydantoin, quaternium-15, imidazolidinyl urea, diazolidinyl urea and 2-bromo-2-nitropropane-1,3-diol. Formaldehyde is a known ocular irritant at 0.05 ppm and at 0.5 ppm, and can make eyes burn, itch, become red and tear. While more blinking, increased tear production and eye closure generally shelter the eye from damage at these low levels,<sup>7</sup> these protections don't help the DED patient with compromised aqueous production and/or evaporative protection, allowing formaldehyde to contribute to ocular surface damage.

**Parabens**

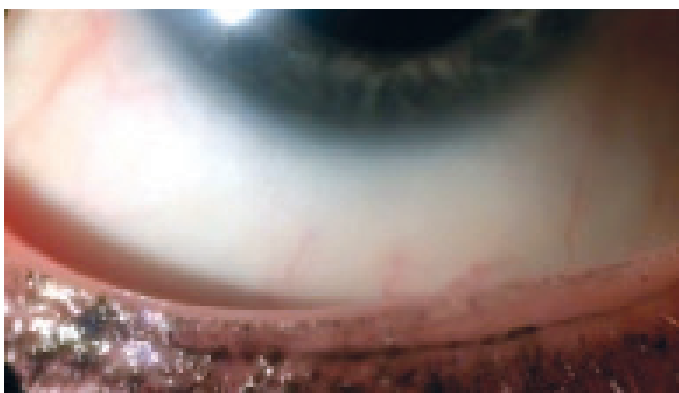
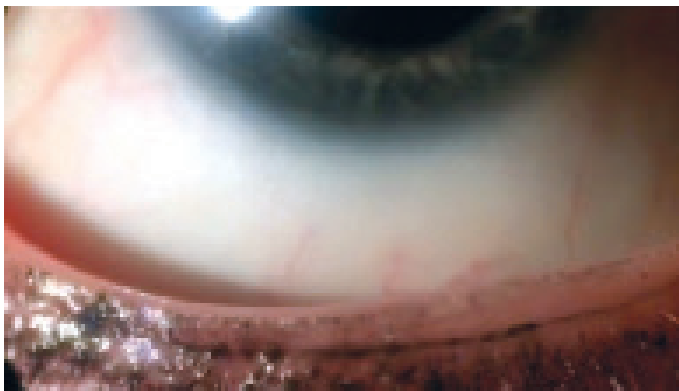
The detrimental effect of estrogen and progesterone hormones on the MGs has been well described.<sup>8</sup> Parabens have a weak estrogenic effect and can inhibit the function of human meibomian gland cells. Methylparaben demonstrates significant and similar toxicity to BAK in human conjunctival and corneal cell cultures.<sup>9</sup>

**Phenoxyethanol**

What smells like a rose but isn't a rose? It is phenoxyethanol. Phenoxyethanol is an alternative non-formaldehyde donating preservative. With it, the amount of parabens needed in a product for adequate contamination control is less. "Paraben free" is a marketing tag and phenoxyethanol is a main way cosmetics companies get around using paraben to cater to the 'natural' and 'vegan' markets. A strong rose- or perfume-like smell is prevalent among mascaras in drug, department and natural foods stores.

**Other ingredients to avoid**

While alcohols speed the cosmetics' drying time, they also dry out native oils and moisture of the lids and ocular surface. Waxes in eyeliners have the potential to obstruct the meibomian gland terminal orifices, thereby limiting meibum delivery to the lid margin lipid reservoir and subsequent delivery onto the tear film. This effect can increase the inflammation-inducing evaporative load of the patient, particularly when eyeliners are used along the eyelid margin covering the meibomian gland orifices in a practice known as 'tight-lining' or "water lining". We see cosmetics-



IMAGES COURTESY OF LESLIE O'DELL, OD

**Figure 1:** Waterproof eyeliner (top) on the lid margin. Note dull appearance of lid margin.

**Figure 2:** Removal of waterproof liner (bottom) with a spud spatula.

'clean' while the synthetic skin conditioners of most facial cleansers make the skin feel moisturized, but the oils that nature intended have been stripped away.

**Preservatives**

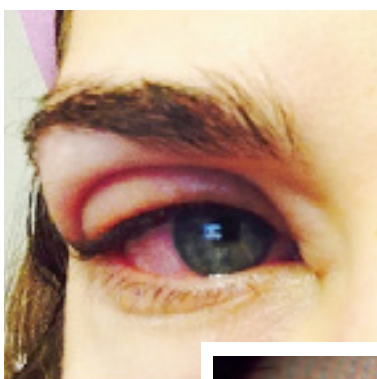While preservatives are important to prevent bacterial and fungal contamination in cosmetics and hygiene products, they also are problematic for the delicate ocular surface. Common preservatives used in cosmetics include: formaldehyde-donating preservatives; parabens; BAK; and phenoxyethanol.

**Formaldehyde**

Formaldehyde, a well-known allergen, is released from formaldehyde-donating preservatives.<sup>6</sup>

associated iatrogenic MG blockage in our OSD patients routinely as outlined in the case study and **Figures 1-2** above, leg-ends at bottom.

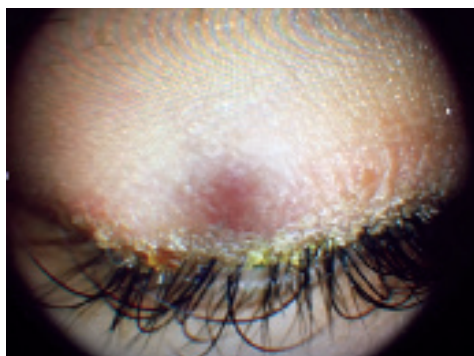Patients should appreciate that their eyelids are delicate and need gentle care: lightly soak (warm compress), gently scrub, avoid soaps/detergents and gently condition (with hyaluronic acid-containing moisturizers). HA moisturizers are excellent humectants for the skin and lashes, but watch out for detrimental co-ingredients



**Figure 5: Marked allergic reaction (left) 1 day after application of eyelash extensions. Patient had extensions removed same day due to allergic reaction.**

**Figure 6: Marked blepharitis (bottom) 7 days after eyelash extension application.**

IMAGES COURTESY OF LAURA M PERIMAN, MD



like parabens (weakly estrogenic)<sup>8</sup> and retinols (toxic to the meibocytes),<sup>10</sup> particularly in ‘anti-aging’ formulations. When details regarding lid hygiene and OTC personal care products and cosmetics are optimized for the OSD patient (female or male), the patient’s daily desiccating stress load is reduced.

### The trouble with lashes

What is the consequence of having these popular, artificial, longer, thicker lashes? The glue acrylates, formaldehyde and solvents are allergenic (see **photos 5-6 at bottom**) and can cause a chemical conjunctivitis when in contact with the tear film (see **photos 3-4 at left**). Additionally, the extensions increase airflow stress and evap-

## Case study: sidebar

I began to realize the scope of the cosmetics and OSD problem years ago while taking care of a beautiful 73-year-old woman with severe DED and stage 3+ MGD loss referred for ‘severe DED non-responsive to treatment’. She had received the appropriate ITF level 3 therapies for years and was still miserable from her DED. Her advanced disease was significantly worse than expected, compared to her risk factors and her peer group. Additionally, her Sjo R (Bausch) test was negative.

History revealed cosmetic surgical procedures, 10+ years of injectable neurotoxins (Bo-Tox) to the forehead and crow’s feet as well as daily application of full makeup (including applying eyeliner to the eyelid margin) and nightly removal with liquid makeup removers. Notably, her DED flare-ups occurred three to four times a year within one to two weeks after her last crow’s feet injection. She was surprised to realize this reported connection.<sup>12</sup>

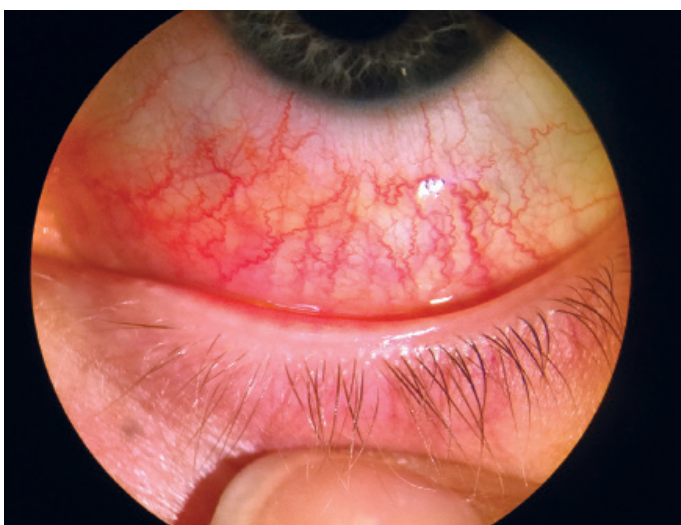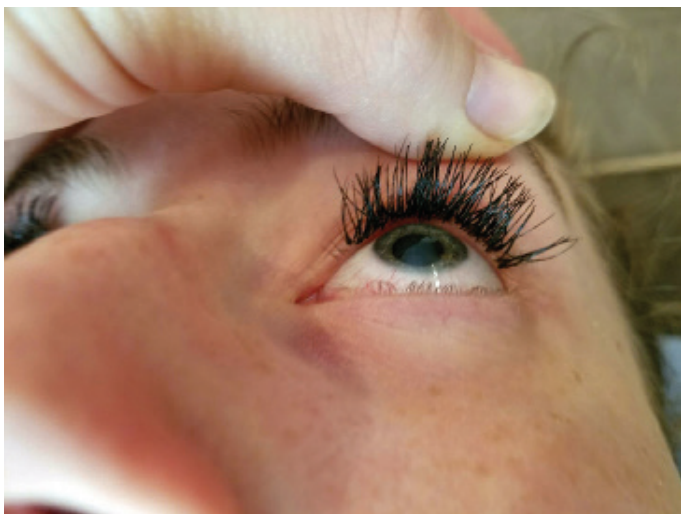At the slit lamp, she had thick eyeliner on the eyelid margin blocking the MG ductules (similar to **photo 1-2 at left**) and tattoo eyeliner under the lashes BLL (known association with tattoo eyeliner and DED),<sup>14</sup> significant eye shadow debris in the tear film and grade 3 MGD with 80% atrophy and drop out. She had pigmented cosmetic micro shards imbedded under her inferior palpebral conjunctiva along with 2+ hyperemia, 3+ lissamine green staining, 3+ fluorescein staining and a TBUT of 3 seconds OU.

I asked her to bring in her makeup to her next appointment, and she did. Particularly impressive was her luxury brand, eye makeup remover that also likely removed the healthy oils of the lipid reservoir, creating a nightly drying and stripping effect. While the actual percentage of BAK was not mentioned on the package nor online, it came after benzyl alcohol (drying) and quaternium-15 (formaldehyde donor preservative), implying the levels were above 1%. This is significantly more BAK exposure than any prescription ophthalmic medication. BAK is known to destabilize the tear film even in healthy patients<sup>9,16</sup> and is epithelial toxic in even small doses.<sup>9,16</sup> BAK also can

*Case Study continued on page 36*

**Figure 3: 23 year old female (top) with marked burning and irritation on same day as application of eyelash extensions.**

**Figure 4: Chemical conjunctivitis (bottom) in same eye due to the eyelash extension adhesive.**



IMAGES COURTESY OF LESLIE O'DELL, OD

oration around the eyes. Mother nature, in her infinite wisdom, designed an optimal eyelash length to lid length ratio. In one study, subjects under age 50 with a lowered ratio (longer lashes) had more dry eye signs and symptoms.<sup>11</sup> The patient pictured above complained of burning and tearing during the glueing process. The glue and solvents likely came in contact with the tear film resulting in the chemical conjunctivitis below.

#### Anti-aging products and OSD

Retin A and its retinoic, retinol and retinyl cousins are wonderful anti-aging products for the face but not for the skin around the eyes. That said, applying Retin A-like products to the face at

bedtime are potential nightly offenders to meibomian gland health. The keratinizing, apoptotic, IL-1B and MMP-inducing effects of retinoic acid have been described in human meibomian gland cell culture (HMGC).<sup>10</sup> Eye care providers need to address Retin A's potential drawbacks as most consumers do not understand what could happen to the eyes. Patients should be told to avoid products that claim 'anti-aging' effects as the anti-aging ingredient could be one of these meibomian gland toxic substances. The best anti-aging product is a paraben-free sunscreen.

#### BoTox and "BoTox in a Jar"

While BoTox can have a relaxing effect on wrinkles in the eye's crow's feet area it is known to correlate with DED.<sup>12</sup> Acetyl-hexapeptide 3, marketed as Argireline, a SNAP-25 fragment of Botulinum toxin, is a common anti-aging additive to luxury products sold as "BoTox in a Jar". This weakly neurotoxic chemical inhibits the facial muscles thereby creating its wrinkle smoothing effect.<sup>13</sup> But this inhibition could also weaken the orbicularis muscle resulting in reduced blink forces, so important for tear wet/spread, lid-lid contact and mechanical expression of meibum into the lipid reservoir and precorneal tear film.

#### Hypoallergenic: just a buzzword

The FDA's less than 1% rule (see above) regarding ingredient concentrations is of particular relevance for patients with allergies to unlisted ingredients in cosmetics.

The authors recently conducted an online survey ([www.SurveyMonkey.com](http://www.SurveyMonkey.com)) of 169 cosmetics users that showed about one in three consumers buys products because they are labeled hypoallergenic. Hypoallergenic is not determined by any federal standards or definitions, it's a term companies use to make their products more appealing to these sensitive consumers. The cosmetics hypoallergenic label does not have federal guidelines or standards.<sup>4</sup> Repeated attempts to legislate standards for the term have met with significant challenges from well-known 'hypoallergenic' cosmetics brands.

Consumers and the patients we serve need to understand that there is no guarantee that a cosmetic will not cause an allergic reaction nor be ocular surface friendly.

*Cosmetics continued on page 46*



*Cosmetics continued from page 36*

### Conclusion

Our online research showed 88.76% (150/169) of consumers do not talk to their eye care providers about their cosmetic use. (Figure 2) 70.42% (119/169) do not look at ingredients when deciding what products to purchase. (Figure 2) With so many hidden chemicals capable of harming our patients' ocular surface we need to start the conversation with them. Start educating patients that their delicate eyelids and ocular surface need thoughtful and special care. What is 'good' for the face and skin may be detrimental to the delicate ocular surface. **OM**

### A few web sites that can help:

Think Dirty, Skin Deep and Good Guide.

Also, the TFOS DEWS II Report ([www.tearfilm.org](http://www.tearfilm.org)) will be published soon and a patient version will be available in multiple languages.

If a patient has adverse reaction to eye cosmetics, the FDA encourages you to report it much like reporting adverse events to medications we prescribe. <https://www.accessdata.fda.gov/scripts/medwatch/index.cfm?action=reporting.home>

### REFERENCES

1. Ng A, Evans K, North RV, Jones L, Purslow C. Impact of eye cosmetics on the eye, adnexa and ocular surface. *Eye Contact Lens* 2016 July 42(4): 211-220.
2. Wax PM. Elixirs, diluents, and the passage of the 1938 Federal Food, Drug and Cosmetic Act. *Ann Intern Med.* 1995 Mar 15;122:45 6-61.
3. Summary of labeling requirements. <http://www.fda.gov/Cosmetics/Labeling/Regulations/ucm126438.htm>
4. FDA Authority Over Cosmetics: How Cosmetics Are Not FDA-Approved, but Are FDA Regulated. <http://tinyurl.com/jtguqyq>
5. Suhalim JL, Parfitt GJ, Xie Y et al. Effect of desiccating stress on mouse meibomian gland function. *OcSurf* 2014:59-68.
6. DeGroot, AC, Flyvholm, MA, Lensen, G, et al. Formaldehyde-releasers: relationship to formaldehyde contact allergy. Contact allergy to formaldehyde and inventory of formaldehyde-releasers. *Contact Dermatitis*. 2009 (61): 63-85
7. [https://www.osha.gov/pls/oshaweb/owadisp.show\\_document?p\\_table=STANDARDS&p\\_id=10078](https://www.osha.gov/pls/oshaweb/owadisp.show_document?p_table=STANDARDS&p_id=10078)
8. The International Workshop on Meibomian Gland Dysfunction: Report of the sub-committee on anatomy, physiology and pathophysiology of the meibomian gland. *IOVS* 2011 (52) 4: 1938-1978
9. Epstein SP, Ahdo M, Marcus E, Asbell PA. Comparative toxicity of preservatives on immortalized corneal and conjunctival epithelial cells. *J of Oc Pharm and Therapeutics*. 2009 (25): 113-119.
10. Ding J, Kam WR, Dieckow J, Sullivan DA. The Influence of 13-cis Retinoic Acid on Human Meibomian Gland Epithelial Cells. *IOVS* 2013 (54): 4341-4350.
11. Rodriguez JK, Corcoran P, Angjeli E, Sundstrom C, Ousler GW. Objective measurement of eyelash parameters and their relation to dry eye disease. *ARVO* 2016 Post-er session

### Case Study continued from page 34

damage goblet cells thereby decreasing mucin, further compromising tear film stability and also desiccating stress-a core mechanism of DED as outlined in the TFOS DEWS Report.<sup>17</sup>

Her waterproof eyeliners had waxes, pine tar extracts and alcohols that were likely contributing to terminal ductule obstruction and irritation of the already severely diseased meibomian glands.

### Patient #2: Dr. O'Dell

Because I transilluminate every patient at the slit lamp and use LipiView II (TearScience) for my meibography images, I find many patients with MG truncation, atrophy and tortuosity. One patient, a 20 year old Caucasian female emmetrope, came in complaining of fluctuating vision. She had significant makeup residue on her lashes although she said she had not put fresh makeup on the day of her exam. She said she had removed it the night before. (Figure 3) She also had significant MG changes (Figure 4), with almost 50% truncation of her glands in both eyes. She used a waterproof eyeliner and mascara daily and applied her eyeliner to the "waterline". Her makeup remover contained chemicals found in paint, acetone derivatives and alcohol, all with the potential to strip her oil reservoir. Her comfort improved significantly after she learned what ingredients to avoid in her cosmetics, how to put on eyeliner by avoiding the waterline and accepting recommendations for less OSD-offending makeup removers. **OM**

12. Ozgur O, Murariu D, Parsa AA, Parsa FD. Dry Eye Syndrome due to Botulinum Toxin Type-A Injection: Guideline for Prevention. *Hawaii J Med Pub Health*. 2012.71: 120-123.
13. Blanes-Mira C, Clemente J, Jodas G, Gil A, Fernandez-Ballester G, Ponsati B, Gutierrez L, Perez-Paya E, Ferrer-Montiel A. A synthetic hexapeptide (argireline) with antiwrinkle activity. *Int J Cosmet Sci*. 2002 Oct;24(5):303-10. doi: 10.1046/j.1467-2494.2002.00153.x.
14. Lee YB, Kim JJ, Hyon JY, Wee WR, Shin YJ. Eyelid tattooing induces meibomian gland loss and tear film instability. *Cornea* 2015 Jul;34(7): 750-755.
15. Baudouin C, deLunardo C. Short term comparative study of topical 2% carboxymethyl chitosan with and without benzalkonium chloride in healthy volunteers. *BJO* 1998; 82: 39-42
16. Noecker R and Miller KV. Benzalkonium chloride in glaucoma medications. *Oc Surf* July 2011 9(3): 159-162. (#2837-A0046). 03May2016. Seattle WA
17. TFOS DEWS Report. *OcSurf* 2007 (5): 1-142.